

CHRONIC DYSPEPSIA IN A MIDDLE-AGED WOMAN WITH NORMAL GASTRIC EMPTYING

Introduction

When common gastrointestinal diseases are eliminated as a cause of nausea and vomiting, gastric neuromuscular disorders, including gastric dysrhythmias, should be considered as potential causes of these symptoms.⁽¹⁾ Gastric dysrhythmias are abnormal myoelectrical activities of the stomach that disrupt normal gastric peristaltic contractions, resulting in inadequate contractions which can alter the gastric emptying rate.⁽²⁾

An Electrogastrogram (EGG) is a non-invasive test of myoelectrical activity of the stomach. Cutaneous electrodes placed on the patient's upper abdomen measure the electrical events that produce normal stomach neuromuscular activities and dysrhythmias associated with nausea and delayed gastric emptying. In humans, the normal frequency is 3 cycles per minute (cpm).⁽³⁾ Bradygastria is an abnormally slow frequency (1.0-2.5 cpm), while tachygastria is an abnormally rapid frequency (3.75-10.0 cpm). This test is typically recorded for 15 minutes in the fasting state and then for 30 minutes after an appropriate test meal or water load.* Water load is often preferred as a provocative test because comparable results can be achieved in less time (30 minutes versus 2 hours) and the effects of secretin, cholecystokinin and other hormonal responses are limited due to the lack of calories in the test meal. Water load also avoids stimulating colonic neuromuscular activity, while still provoking symptoms such as bloating and nausea.

The utility of EGG as an aid in diagnosing and treating gastric dysrhythmias is demonstrated in the following case.

* Vispace proprietary EGGASAS© software compares patient results with control values that were established using a water load as the test meal.

Patient History

A 56-year old woman presented with chronic early satiety and nausea. An acute episode of severe epigastric pain, nausea and vomiting led to hospitalization. No specific cause of the acute symptoms was found. Symptoms persisted for months and the patient could not eat regular food. A gastroenterological consultation was obtained and physical examination was within normal limits. No abdominal tenderness, masses or organomegaly were found.

Evaluation Procedures

An upper GI series, abdominal CT scan and upper endoscopy were all normal, although the pylorus was difficult to traverse. A nuclear solid-phase gastric emptying time (GET) test was normal at 62% emptied in two 2 hours (in this practice region normal is >60%). Colonoscopy was normal as were the results of a CT scan of the head.

Vispace™ Electrogastrogram Analyzer Results

EGG test showed a probable tachygastria with some normal 3 cpm activity and persistent increase in tachygastria before and after water load. The patient ingested 400 ml in five minutes during the water load test (normal is ~600 ml). The Running Spectral Analysis (RSA) showed some peaks at 3 cpm and some smaller peaks in the tachygastria range. The EGG Summary Sheet showed an increase in 3 cpm activity 10 minutes after ingestion of water and an increase in percentage of power in the tachygastria range, indicating a diagnosis of tachygastria.

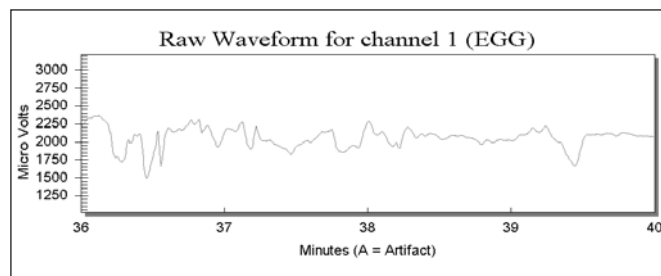


Figure 1. EGG Signal Pre-intervention. Rhythm shows abnormally rapid activity, indicating a possible tachygastria.



Kenneth L. Koch, MD
Professor of Internal Medicine
Chief, Section on
Gastroenterology
Wake Forest University School
of Medicine
Bowman Gray Campus
Winston-Salem, NC

Former Professor of Medicine,
Division of Gastroenterology
The Milton S. Hershey Medical
Center
The Pennsylvania State
University
Hershey, PA

Co-founder, International
Electrogastrography Society
(IEGGS)
Chairman and Co-founder,
3CPM Company, Inc.

Member
American College of
Gastroenterology
American Gastroenterology
Association
American Motility Society
American Physiological
Society

Intervention

The patient was started on Reglan but was unable to tolerate the drug. Erythromycin and domperidone were tried but did not decrease her symptoms. Patient was then given tegaserod, 6 mg BID, for three months and symptoms showed marked improvement.

Post-Intervention EGG Results

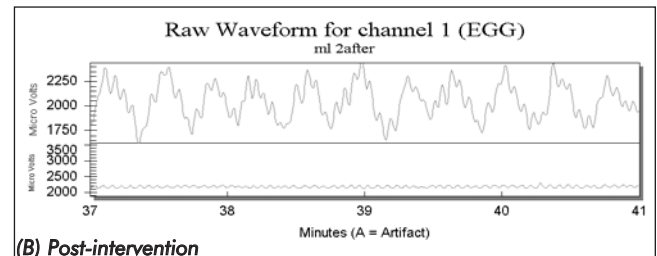
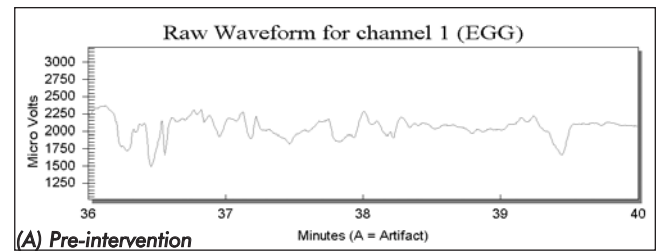
Following three months of tegaserod treatment, another test was performed using the Visipace Electrogastrogram Analyzer. The follow-up test recorded strong 3 cpm waves at baseline and in response to water load. Furthermore, the patient was able to consume 600 ml during water load. The RSA showed consistent 3 cpm peaks before and after water load. Finally, the percentage distribution in the EGG Summary Report showed increased 3 cpm percentages after water load and resolution of the tachygastria.

Conclusion

The patient had symptoms of functional dyspepsia, a low normal GET and probable tachygastria. Prokinetic drug therapy with tegaserod eradicated the symptoms, corrected the tachygastria and restored regular 3 cpm activity. This is an example of eradication of a gastric dysrhythmia by a prokinetic (anti-arrhythmic) drug and resolution of upper GI symptoms.

References

1. Koch KL. Unexplained nausea and vomiting. *Current Treatment Options in Gastroenterology* 2000; 3:303-313.
2. Koch KL, Stern RM. Functional disorders of the stomach. *Semin Gastrointest Dis* 1996; 7:185-195.
3. Hinder RA, Kelly KA. Human gastric pacesetter potential. Site of origin, spread and response to gastric transection and proximal gastric vagotomy. *Am J Surg* 1978;133:29-33.



of EGG Signal Post-intervention. Rhythm in (B) shows resolution of tachygastria seen in (A) and restoration of more normal 3 cpm activity.