

REFLUX-RELATED DYSPEPSIA OR GERD+ IN MIDDLE-AGED MAN

Introduction

A distinctive Electrogastragram (EGG) pattern was discovered that has actually defined a unique GERD-associated type of gastroparesis known as GERD+.⁽¹⁾ An EGG is a non-invasive test that uses cutaneous electrodes placed on the patient's upper abdomen to measure myoelectrical activity of the stomach. In humans, the normal frequency is 3 cycles per minute (cpm).⁽²⁾ Bradygastria is an abnormally slow frequency (1.0-2.5 cpm), while tachygastria is an abnormally rapid frequency (3.75-10.0 cpm). This test is typically recorded for 15 minutes in the fasting state and then for 30 minutes after an appropriate test meal or water load.* Water load is often preferred because comparable results can be achieved in less time (30 minutes versus 2 hours) and the effects of secretin, cholecystokinin and other hormonal responses are limited due to the lack of calories in the test meal. Water load also avoids stimulating colonic neuromuscular activity, while still provoking symptoms such as bloating and nausea.

An example of this condition is presented in the following case.

* Vispace proprietary EGGAS© software compares patient results with control values that were established using a water load as the test meal.

Patient History

A 43-year old male, slightly overweight, physically inactive. Presenting symptoms included postprandial bloating, abdominal distention, eructation, sporadic nausea, significant retrosternal and laryngeal burning, nocturnal aspiration and regurgitation, and early satiety. The symptoms had been progressive over the past 2-3 years. Patient was treated with single- and double-dose proton pump inhibitors, which initially improved all symptoms. Over the past two years, however, symptoms persisted despite increasing dose and frequency of medication.

Evaluation Procedures

An Esophagogastroduodenoscopy (EGD) showed Barrett's esophagus, grade I esophagitis, gastritis, and duodenitis. The LES was noted to be incompetent. Esophageal motility was normal. Nuclear solid-phase gastric emptying time (GET) scan was normal at 89% emptied at 2 hours (in this practice region normal is 50% emptied in 90 minutes). Patient was scheduled to undergo correction of reflux by the Stretta procedure. An EGG test was performed due to the prominent dyspeptic symptoms.

Vispace™ Electrogastragram Analyzer Results

EGG test was abnormal. There was a mixed dysrhythmia with tachygastria, poor 3 cpm activity and inversion of the normal pattern in the bradygastria frequency in response to water load. The total water load tolerated by the patient was 350 ml (normal is ~600 ml). The test revealed the etiology of the dyspepsia to be reflux-related or GERD+.

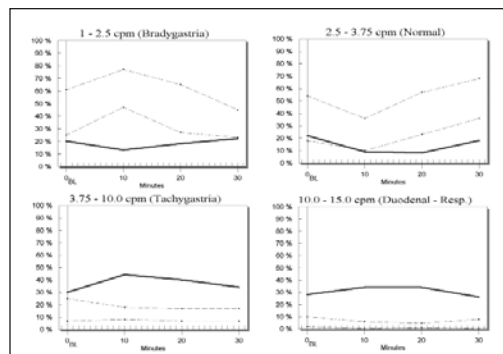



Figure 1. EGG Summary Report Pre-intervention. Patient results fall outside controls, indicating a mixed dysrhythmia.



Mark D. Noar, MD
 Director & CEO
 Endoscopic Microsurgery Associates, PA
 Therapeutic Endoscopy &
 Gastroenterology
 Baltimore, MD

Director & CEO
 The Endoscopy Center at Towson, Inc.
 The Endoscopy Center at Bel Air, LLC
 Towson, MD
 Maryland Gastroenterology
 Network, Inc. Baltimore, MD

Board of Directors & Legislative Chair
 Maryland Ambulatory Surgery
 Association
 Annapolis, MD

Director
 Digestive Health Education
 Foundation
 The Hepatitis Study Center
 The Crohn's/Colitis Study Center

Outside Director, 3CPM Company, Inc.

Member
 American College of
 Gastroenterology
 American Gastroenterological
 Association
 American Society for Gastrointestinal
 Endoscopy
 American College of Physicians
 Baltimore County Medical Society
 MED CHI State Medical Society

Intervention

Patient underwent a Stretta procedure for refractory reflux and dyspepsia. Within two months of the procedure, all symptoms of bloating and satiety had ceased. Reflux symptoms were completely controlled. Patient was able to eat a broader variety of foods without symptoms.

Post-Intervention EGG Results

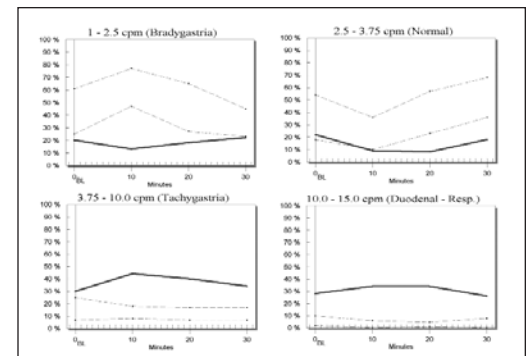
A repeat study was performed eight months after the Stretta procedure. Patient continued to be asymptomatic and was off all medications. Test showed resolution of the tachygastria, with normalization of the 3 cpm pattern.

Conclusion

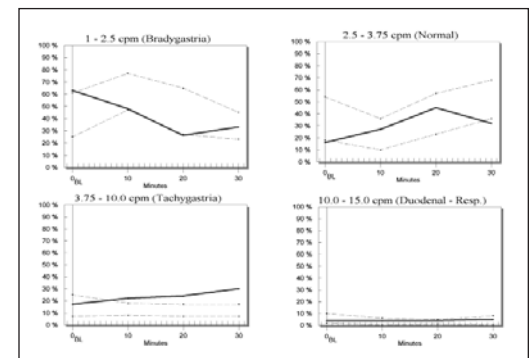
The dyspepsia associated with the reflux symptomatology was directly related to the reflux disease. This has become known as GERD+. With the correction of the reflux, the dyspeptic symptoms also improved. The Visipace Electrogastrogram Analyzer was able to document that the dyspepsia was due to GERD+, which enabled the physician to assure the patient that the symptoms would be expected to improve with correction of his reflux disease with Stretta.

References

1. Noar M, Koch KL, Xu L. Spectrum of gastric neuromuscular dysfunction in patients with GERD plus dysmotility-like dyspepsia (GERD+). *Gastroenterology* 2002; 122:A416.
2. Hinder RA, Kelly KA. Human gastric pacesetter potential. Site of origin, spread and response to gastric transection and proximal gastric vagotomy. *Am J Surg* 1978;133:29-33.



(A) Pre-intervention



(B) Post-intervention

Figure 2. Resolution of GERD+. Patient results in (B) now fall within control ranges. Mixed dysrhythmia in (A) is resolved and a more normal 3 cpm activity exists.