

USE OF ELECTROGASTROGRAPHY IN THE DETECTION OF FUNCTIONAL PYLORIC OUTLET OBSTRUCTION

Introduction

An Electrogastrogram, or EGG, is a non-invasive test that detects the stomach's pacesetter potential activities, much like the electrocardiogram (ECG) detects electrical events occurring in the heart.⁽¹⁾ In humans, the relevant frequency ranges measured in cycles per minute (cpm), are as follows:

- Bradygastria (1.0-2.5 cpm) - abnormally slow myoelectrical activities
- Normal (2.5-3.75 cpm)
- Tachygastria (3.75-10.0 cpm) - abnormally rapid myoelectrical activities
- Duodenal/Respiratory (10.0-15.0 cpm)

Gastric myoelectrical activity recorded during the EGG test can reveal a unique pattern in patients with gastroparesis due to mechanical or functional obstruction of the stomach outlet.⁽²⁾

The utility of EGG as an aid in diagnosing and treating a functional pyloric outlet obstruction is demonstrated in the following case.

Patient History

A 44-year old female presented with a chronic history of GERD, bloating, post-prandial fullness and nausea. The patient was taking PPI therapy daily. GERD symptoms of retrosternal burning were relieved by medication. Bloating, early satiety, nausea and post-prandial fullness were unchanged. Physical exam was remarkable only for upper abdominal distention and a positive succussion splash. Continued weight loss and anorexia had developed as a complication of condition.

Evaluation Procedures

Nuclear solid phase gastric emptying scan revealed only 39% emptying at 90 minutes, confirming the diagnosis of gastroparesis. EGD revealed reflux esophagitis, mild gastritis and a normal appearing pyloric sphincter.

Diagnostic Goal

An EGG with water load test (Visipace™ Electrogastrogram Analyzer, Model No. VP200, E-Z-EM, Inc.) was planned to determine the etiology of the gastroparesis and to evaluate for potentially correctable causes of the delayed gastric emptying. In particular, the goal was to determine if the cause of the gastroparesis was due to functional pyloric obstruction, GERD+ reflux-related dysmotility, or a primary motility disorder, and then to determine the best corrective action. The possible alternative treatment strategies may include dilation of the pyloric sphincter, endoscopic or surgical correction of GERD, or medication, respectively.

Visipace Electrogastrogram Analyzer Results

The EGG results were remarkable for high baseline and post water load 3-cpm activity, in the absence of tachygastria or bradygastria. This picture is characteristic of gastric outlet obstruction, which is amenable to pyloric balloon dilation.

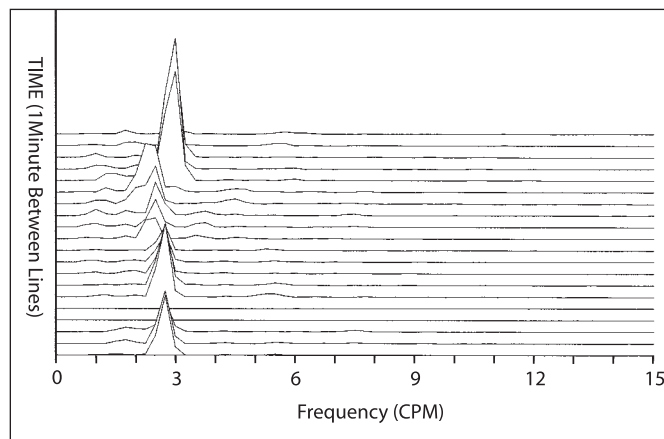


Figure 1. EGG Running Spectral Analysis (RSA) showing 3-cpm activity.



Mark D. Noar, MD

Director & CEO
Endoscopic Microsurgery Associates, PA
Therapeutic Endoscopy &
Gastroenterology
Baltimore, MD

Director & CEO

The Endoscopy Center at Towson, Inc.
The Endoscopy Center at Bel Air, LLC
Towson, MD
Maryland Gastroenterology
Network, Inc. Baltimore, MD

Board of Directors & Legislative Chair
Maryland Ambulatory Surgery
Association
Annapolis, MD

Director

Digestive Health Education
Foundation
The Hearburn and Reflux Center
The Hepatitis Study Center
The Crohn's/Colitis Study Center

Outside Director, 3CPM Company, Inc.

Member

American College of
Gastroenterology (ACG)
American Gastroenterological
Association (AGA)
American Society for Gastrointestinal
Endoscopy
American College of Physicians
Baltimore County Medical Society
MED CHI State Medical Society



Photo from E-Z-EM, Inc.

An EGG with water load test allows the gastroenterologist to diagnose a gastric dysrhythmia or document normal gastric electrical activity. The EGG test is typically recorded for 10-15 minutes in the fasting state and then for 30 minutes after the water load.

A water load test avoids the confounding effects of caloric meals, reflects gastric capacity, takes less time to administer than a caloric meal (30 minutes versus 2 hours), and the results are reproducible.*

During the EGG test, the patient sits comfortably in a chair. Respiration should be tracked during the EGG recording to help identify motion artifacts. Three electrodes are positioned on the epigastrium. These electrodes are connected to a module.

* Koch KL, Hong S-P, Xu L. Reproducibility of gastric myoelectrical activity and the water load test in patients with dysmotility-like dyspepsia symptoms and in control subjects. *J Clin Gastroenterol* 2000; 31(2):125-129.

Intervention

An EGD was performed. During the procedure a thru-the-scope 20 mm balloon dilation was performed for a total time of 2 minutes.

Post-Intervention EGG Results

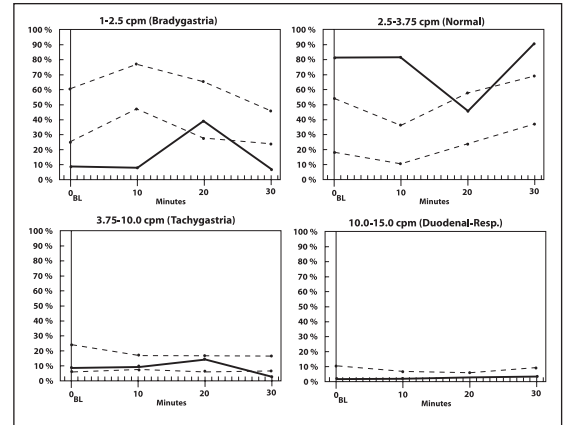
Several weeks after the pyloric dilation, a repeat nuclear gastric emptying scan showed normalization of the emptying of the stomach, with 79% emptying at 90 minutes. A repeat EGG was performed. The previously elevated 3-cpm activity returned to normal. The patient became asymptomatic following the pyloric dilation.

Conclusion

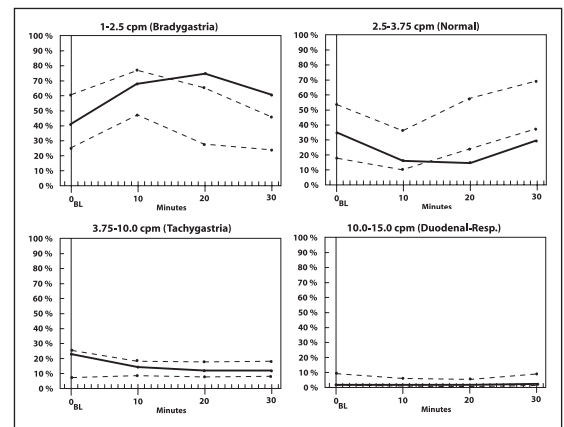
In patients with gastroparesis, as documented via nuclear gastric emptying scan, the EGG study was able to detect the etiology of the gastroparesis and allow corrective measures to be taken to treat the underlying condition. In this case, EGG was able to detect functional pyloric outlet obstruction, thereby expediting the understanding of the cause of the disease, allowing for a more timely and permanent correction of the condition.

References

1. Koch KL, Stewart WR, Stern RM. Effect of barium meal on gastric electromechanical activity in man. A fluoroscopic-electrogastrographic study. *Dig Dis Sci* 1987; 32(11):1217-1222.
2. Koch KL, Stern RM, Stewart WR, Vasey MW. Gastric emptying and gastric myoelectrical activity in patients with diabetic gastroparesis: Effects of long-term domperidone treatment. *The American Journal of Gastroenterology* 1988; 84(9):1069-1075.



(A) Pre-intervention



(B) Post-intervention

Figure 2. Resolution of EGG pattern post-intervention. Elevated 3 cpm activity (A) returned to normal. Patient's patterns of movement more closely match those of control values (B).